



## A novel INDEL mutation in the EDA gene resulting in a distinct X- linked hypohidrotic ectodermal dysplasia phenotype in an Italian family

Callea, M., Nieminen, P., Willoughby, C., Clarich, G., Yavuz, I., Vinciguerra, A., Di Stazio, M., Giglio, S., Sani, I., Maglione, M., Pensiero, S., Tadini, G., & Bellacchio, E. (in press). A novel INDEL mutation in the EDA gene resulting in a distinct X- linked hypohidrotic ectodermal dysplasia phenotype in an Italian family. *Journal of the European Academy of Dermatology and Venereology*, 30(2), 341-343. <https://doi.org/10.1111/jdv.12747>

[Link to publication record in Ulster University Research Portal](#)

### Published in:

Journal of the European Academy of Dermatology and Venereology

### Publication Status:

Accepted/In press: 30/09/2014

### DOI:

[10.1111/jdv.12747](https://doi.org/10.1111/jdv.12747)

### Document Version

Publisher's PDF, also known as Version of record

### General rights

Copyright for the publications made accessible via Ulster University's Research Portal is retained by the author(s) and / or other copyright owners and it is a condition of accessing these publications that users recognise and abide by the legal requirements associated with these rights.

### Take down policy

The Research Portal is Ulster University's institutional repository that provides access to Ulster's research outputs. Every effort has been made to ensure that content in the Research Portal does not infringe any person's rights, or applicable UK laws. If you discover content in the Research Portal that you believe breaches copyright or violates any law, please contact [pure-support@ulster.ac.uk](mailto:pure-support@ulster.ac.uk).

## LETTER TO THE EDITOR

## A novel INDEL mutation in the EDA gene resulting in a distinct X-linked hypohidrotic ectodermal dysplasia phenotype in an Italian family

### Editor

X-Linked Hypohidrotic Ectodermal Dysplasia (XL-HED; MIM 305100) is characterized by hypodontia, misshaped teeth, hypohidrosis, sparse hair, peculiar facial features,<sup>1,2</sup> and occurs in less than 1 in every 100.000 individuals.<sup>1</sup> XL-HED is caused by mutations in the Ectodysplasin-A (EDA) gene located at Xq12-q13 with more than 100 causative mutations reported to date.<sup>1,3,4</sup> The identification of disease-causing mutations confirms the diagnosis, however, does not automatically imply a genotype–phenotype correlation.

We identified an Italian family with XL-HED resulting from a novel mutation. Two members of the family (first degree cousins) (Fig. 1a) presented classic symptoms of XL-HED, sparse and blonde hairs, almost absent eyelashes and eyebrows, pointed chin, frontal bossing, saddle nose, hypohidrosis, atopic dermatitis, nasal crusting and ear keratin debris.<sup>5</sup> Of note they also showed unilateral absence of meibomian glands in the eyelid (an ocular marker of ectodermal dysplasia)<sup>6</sup> and a complete absence (agenesis) of both deciduous and permanent teeth (Fig. 1b,c,d). The proband (IV:2) (Fig. 1a) was male and examined aged 8 years in the Department of Pediatric Stomatology, Children Hospital Burlo Garofolo, Trieste. According to the Helsinki declaration, after informed written consent, his genomic DNA was analysed and an INDEL mutation (c.456\_468del113insT

p.Arg152\_156insdel) was found in exon 3 of the EDA-A1 gene (Fig. 2a).

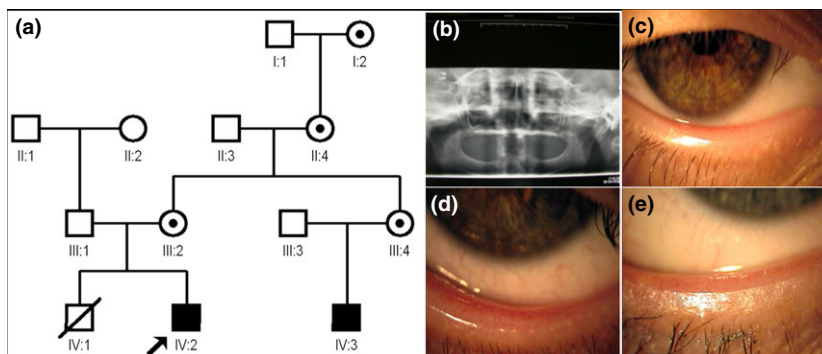
Within the four generation pedigree (Fig. 1a) there were two affected male individuals (IV:2 – the proband – and IV:3 aged 19 years) born to phenotypically normal fathers (III:1; III:3). Both mothers (III:2; III:4), and the grandmother (II:4) and grandgrandmother (I:2) showed a mild HED phenotype and bilateral absence of meibomian glands (Fig. 1e). The diagnosis of XL-HED in these family members relied on clinical features as genetic analysis could not be carried out due to their moving to a foreign country.

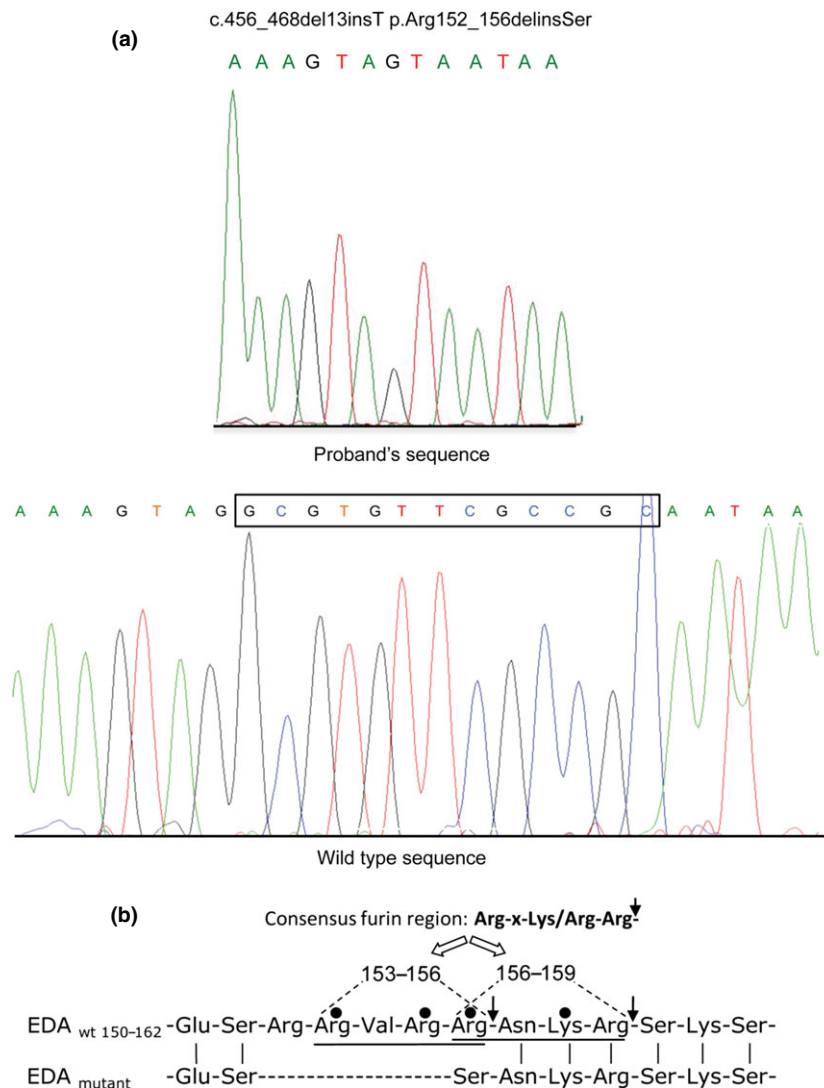
The novel INDEL mutation affects the EDA region processed by furin-like proteases that specifically recognize the Arg(P1)-x(P2)-Lys/Arg(P3)-Arg(P4)- motif producing a cleavage between the arginine in position P4 and its C-terminally adjacent residue.

EDA contains two overlapping motifs (Fig. 2b), with proteolysis occurring predominantly at the second motif.<sup>6</sup> Both motifs are abolished by the mutation presented in this study. In particular, this mutation produces complete loss/modification of the residues composing the first consensus motif, while Arg156, which is shared by both motifs, is turned into a serine. Thus, also the second motif is affected and the resulting Arg156Ser change is already reported as pathogenic.<sup>7</sup> The novel INDEL mutation is expected to fully abrogate the proteolysis of EDA by furin-like proteases, therefore preventing the release of the soluble TNF domain of the protein.

This novel INDEL mutation is therefore likely to interfere with the very early stage of tooth formation, i.e. dental lamina initiation and placode formation,<sup>8</sup> by disturbing the key-transcription factors PITX2 and LEF1.<sup>8,9</sup> Meibomian glands are formed from an ectodermal placode<sup>10</sup> and alterations or absence of both meibomian glands is a reliable ocular finding in

**Figure 1** (a) Pedigree of Italian family affected by XL-HED. Affected males are indicated by filled squares, and female carriers are identified by circles with a dot at their centre. The proband is identified by an arrow. (b) Orthopantomography showing complete anodontia; (c) Absence of the meibomian glands in proband's right eye; (d) Presence of meibomian glands in proband's left eye; (e) Proband's mother: absence of the meibomian gland openings.





**Figure 2** (a) Chromatogram of the EDA mutation. Sanger sequencing identified a novel, mutation c.456\_468del13insT;p.Arg152\_156delinsSer in exon 3 of EDA gene; (b) Sequence alignment of the wild type Ectodysplasmin-A in the amino acid interval 150-162 and the corresponding region in the p.Arg152\_156delinsSer mutant. The two Arg-x-Lys/Arg-Arg- motifs recognized by furin-like proteases present as partially overlapping tandem sequences along residues 153-156 and 156-159 in the wild type protein are highlighted (the vertical arrows indicate the cleavable amide bonds). The vertical lines mark residues that are unchanged in the wild type and in the mutant protein. The black circles indicate residues affected by missense mutations already associated with ectodermal dysplasia. It can be noticed that the residues in the p.Arg152\_156delinsSer mutant can no longer contribute to the formation of any of the two consensus motifs cleaved by furin-like proteases since all the residues in the first Arg-x-Lys/Arg-Arg- motif are either deleted or modified, while the critical Arg at P1 position (Arg 156) in the second motif is turned into a serine.

ectodermal dysplasia patients. The unilateral absence of meibomian glands in the two affected family members is a unique finding which remains to be explained. Herein we report a novel EDA-1 INDEL mutation in XL-HED in an Italian family resulting in a unique ocular and dental phenotype further expanding the genotype-phenotype spectrum of XL-HED.

M. Callea,<sup>1,†</sup> P. Nieminen,<sup>2,\*</sup> C.E. Willoughby,<sup>3,\*</sup> G. Clarich,<sup>1</sup> I. Yavuz,<sup>4</sup> A. Vinciguerra,<sup>1</sup> M. Di Stazio,<sup>5</sup> S. Giglio,<sup>6,7</sup> I. Sani,<sup>8</sup> M. Maglione,<sup>5</sup> S. Pensiero,<sup>1</sup> G. Tadini,<sup>8,9</sup> E. Bellacchio<sup>10</sup>

<sup>1</sup>Institute for Maternal and Child Health – IRCCS ‘Burlo Garofolo’, Trieste, Italy, <sup>2</sup>Department of Oral and Maxillofacial Diseases, University of

Helsinki, Institute of Dentistry, Helsinki University Central Hospital, Helsinki, Finland, <sup>3</sup>Department of Eye and Vision Science, University of Liverpool, Institute of Ageing and Chronic Disease, Liverpool, UK, <sup>4</sup>Department of Pediatric Dentistry, Faculty of Dentistry, Dicle University, Diyarbakir, Turkey, <sup>5</sup>Department of Medical, Surgical and Health Sciences, University of Trieste, Trieste, Italy, <sup>6</sup>Medical Genetics Section, Department of Clinical Pathophysiology, University of Florence, Florence, Italy, <sup>7</sup>Medical Genetics Unit, Meyer Children's University Hospital, Florence, Italy, <sup>8</sup>Fondazione IRCCS Cà Granda - Ospedale Maggiore Policlinico Milano, Milan, Italy, <sup>9</sup>Department of Pediatric Dermatology, University of Milan, Milan, Italy, <sup>10</sup>Bambino Gesù Children's Hospital IRCCS, Research Laboratory, Rome, Italy

†Correspondence: M. Callea. E-mail: mcallea@gmail.com

\*These two authors have equally contributed to the manuscript and should be considered both as second author.

## References

- 1 Chassaing N, Bourthoumieu S, Cossee M, Calvas P, Vincent MC. Mutations in EDAR account for one quarter of non ED1-related hypohidrotic ectodermal dysplasia. *Hum Mutat* 2006; **27**: 255–259.
- 2 Itin PH, Fistarol SK. Ectodermal dysplasias. *Am J Med Genet C Semin Med Gen* 2004; **131C**: 45–51.
- 3 Paakkonen K, Cambiaghi S, Novelli G *et al*. The mutation spectrum of the EDA gene in X-linked anhidrotic ectodermal dysplasia. *Hum Mutat* 2001; **17**: 349.
- 4 Guazzarotti L, Tadini G, Mancini GE *et al*. Phenotypic heterogeneity and mutational spectrum in a cohort of 45 Italian males subjects with X-linked ectodermal dysplasia. *Clin Genet* 2014; doi:10.1111/cge.12404. [Epub ahead of print]
- 5 Callea M, Teggi R, Yavuz I *et al*. Ear nose throat manifestations in hypohidrotic ectodermal dysplasia. *Int J Pediatr Otorhinolaryngol* 2013; **77**: 1801–1804.
- 6 Allali J, Roche O, Monnet D, Brezin A, Renard G, Dufier J1. Anhidrotic Ectodermal Dysplasia: 'congenital ameibomia'. *J Fr Ophthalmology* 2007; **30**: 525–528.
- 7 Chen Y, Molloy SS, Thomas L *et al*. Mutations within a furin consensus sequence block proteolytic release of ectodysplasin-A and causes X-linked hypohidrotic ectodermal dysplasia. *Proc Natl Acad Sci USA* 2001; **98**: 7218–7223.
- 8 Aoki N, Ito K, Tachibana T, Ito M. A novel Arginine-Serine mutation in EDA 1 in a Japanese family with X-linked anhidrotic ectodermal dysplasia. *J Invest Dermatol* 2000; **115**: 329–330.
- 9 Thesleff I. The genetic basis of tooth development and dental defects. *Am J Med Genet A* 2006; **140A**: 2530–2535.
- 10 Mikkola ML. Genetic basis of skin appendage development. *Semin Cell Dev Biol* 2007; **18**: 225–336.

DOI: 10.1111/jdv.12747